

INVESTIGATION OF PARASITIC CONTAMINATION OF PROTEIN PRODUCTS PRODUCED IN ISFAHAN INDUSTRIAL SLAUGHTERHOUSE

INVESTIGACIÓN DE CONTAMINACIÓN PARASITARIA DE PRODUCTOS PROTEICOS PRODUCIDOS EN EL MATADERO INDUSTRIAL DE ISFAHAN

Omid Mohammadi¹ ; Amir Shakerian¹ * .

¹ Islamic Azad University, Shahrekord Branch, Shahrekord, Iran. angodinov@yahoo.com

*Corresponding author: Amir Shakerian, email: angodinov@yahoo.com

Información del artículo:

Artículo original

DOI: <https://doi.org/10.33975/riuq.vol35n1.1177>

Recibido: 22 marzo 2023; Aceptado: 9 mayo 2023

ABSTRACT

This study aims to investigate the common and important parasitic infections that reduce the nutritional value and also cause serious damage and disrupt the functioning of systems such as the liver and bile ducts as a vital organ of the human body and livestock. In order to investigate the mentioned parasitic infections in the autumn season, 60,881 livestock, including 32,213 sheep, 21,368 goats, 6,186 cows, 1,059 ostriches and 55 camels were slaughtered in Fasaran Slaughterhouse in 2022. **Method:** According to the working timetable and the existence of two slaughter lines, organs such as liver, lung, heart and carcass are examined macroscopically, then samples suspected of contamination are separated for microscopic examination. **Results:** The prevalence rate of hydatid cyst parasite was 49.44%, including 30.02% in sheep, 6.78% in goats, and 12.63% in cows. Moreover, the severity of infection in the liver of sheep, goats, and cows was 10, 1.04, and 2.89%, respectively. Also, the severity of lung contamination in sheep, goats, and cows was 20.02, 5.73 and 9.46% respectively. The prevalence rate of cysticercosis parasite was 0.38%, in a way that, infection rate in the carcasses of sheep, goats, and cows was 0.27%, 0.60%, and 0.40%, respectively. **Conclusion:** According to the results, it can be concluded that parasitic infection can play an important role in reducing the nutrients of infected tissues, and in case of human infection, pathological complications can affect the functioning of body organs and disrupt and cause serious harm to human health.

Keywords: liver histopathology; fasciola; dicrocoelium; hydatid cyst; cysticercosis.

Cómo citar: Mohammadi, Omid., & Shakerian, Amir. (2023). Investigation of parasitic contamination of protein products produced in Isfahan industrial slaughterhouse. *Revista de Investigaciones Universidad del Quindío*, 35(1), 373-390. <https://doi.org/10.33975/riuq.vol35n1.1177>

ISSN: 1794-631X e-ISSN: 2500-5782

Esta obra está bajo una licencia Creative Commons
Atribución-NoComercial-SinDerivadas 4.0 Internacional.



RESUMEN

Este estudio tiene como objetivo investigar las infecciones parasitarias comunes e importantes que reducen el valor nutricional y también causan daños graves y alteran el funcionamiento de sistemas como el hígado y las vías biliares como órgano vital del cuerpo humano y el ganado. Con el fin de investigar las infecciones parasitarias mencionadas en la temporada de otoño, 60.881 cabezas de ganado, incluidas 32.213 ovejas, 21.368 cabras, 6.186 vacas, 1.059 avestruces y 55 camellos fueron sacrificados en el Matadero de Fasaran en 2022. **Método:** Según el horario de trabajo y la existencia de dos líneas de matanza, los órganos como el hígado, los pulmones, el corazón y la canal se examinan macroscópicamente, luego las muestras sospechosas de contaminación se separan para el examen microscópico. **Resultados:** La tasa de prevalencia del parásito del quiste hidatídico fue de 49,44%, incluyendo 30,02% en ovejas, 6,78% en cabras y 12,63% en vacas. Además, la gravedad de la infección en el hígado de ovejas, cabras y vacas fue de 10, 1,04 y 2,89%, respectivamente. Asimismo, la severidad de la contaminación pulmonar en ovinos, caprinos y bovinos fue de 20,02, 5,73 y 9,46% respectivamente. La tasa de prevalencia del parásito cisticercosis fue de 0,38%, de manera que la tasa de infección en las canales de ovinos, caprinos y bovinos fue de 0,27%, 0,60% y 0,40%, respectivamente. **Conclusión:** De acuerdo con los resultados, se puede concluir que la infección parasitaria puede desempeñar un papel importante en la reducción de los nutrientes de los tejidos infectados y, en caso de infección humana, las complicaciones patológicas pueden afectar el funcionamiento de los órganos del cuerpo y alterar y causar daños graves a salud humana.

Palabras clave: histopatología hepática; fasciola; dicroceleio; quiste hidatídico; cisticercosis.

INTRODUCTION

Along with the growth of knowledge and technology regarding the elimination of food risk factors, the spread of parasitic diseases has also increased, so that according to the report of the Food and Agriculture Organization, the economic losses caused by parasitic diseases in developed countries are 16% and in developing countries 30% of the total livestock production. One of the problems of the livestock husbandry industry and the causes of the death of livestock is the loss of food resources, which, due to the presence of 75% of the world's population in developing countries, the amount of economic damage caused by parasitic diseases is significant. In scientific sources, they are still considered as food and water pathogens (zoonosis) causing direct and indirect harmful damages (environmental pollution, plants, soil, water, etc.). Moreover, these pathogens can cause serious damage to the sensitive and vital organs of the body and seriously threaten the health of society.

Therefore, parasitic infections in Iran cause a lot of costs due to diagnosis, prevention and treatment in the livestock and human sectors every year. Due to the wide spread and variety of antigens and having extremely diverse mechanisms against the immune system, they have created many problems for the emergence of effective vaccines. Due to the fact that they lack the ability to reproduce in the environment, there are limitations regarding their isolation methods, while most microbial diseases can be identified and treated due to the occurrence of obvious clinical symptoms. Because of the enrichment in bacterial contamination of food and by implementing effective vaccination programs, the spread of these diseases can be prevented to a large extent and action can be taken to eradicate them. Conducting serological tests and concentration methods and, in general, strategic antiparasitic fight, have lower costs compared to other methods, but this is not accepted by livestock farmers. Due

to the lack of laboratory tests to diagnose parasitic diseases in livestock, slaughterhouses can still be a useful source for evaluating the epidemiological aspects of parasitic diseases. Also, considering that the histopathological complications caused in humans, despite the harsh medical ethics and legal regulations, rely on livestock findings, and considering the endemicity and prevalence of many of these important parasitic infections from the point of view of zoonotics in the country, it was decided to conduct more detailed studies on the complications and problems in terms of the function of the involved organ, as well as the histopathological complications and its generalization to the cases of human infection. This study was conducted using slaughtered samples to clarify the dark corners of their histopathological changes, having a useful comparative value in distinguishing them from each other as well as from other diseases and infections.

In the slaughterhouse of Sandaj city, the degree of contamination of the liver with *Fasciola* in cows was higher (6.25%) and less in goats (4.4%), and the contamination of the liver with *Dicrocoelium* was highest in sheep (3.35%) and lowest in goats (2.2%). Moreover, liver infection with hydatid cyst was highest in cows (6.25%) and lowest in goats (2.2%). The rate of lung infection with hydatid cyst is highest in goats (11.11%) and lowest in sheep (7.32%). Worm contamination was not observed in the lungs of cows (Dehkordi et al., 2017).

In the industrial slaughterhouse of Mazandaran, the highest prevalence of disease in recorded livers was related to hydatid cyst (in sheep and lambs, the highest amount is 6.01% and the lowest amount in goats and kids is 2%). In examining lungs of slaughter livestock, the highest contamination was related to hydatid cysts, which was 14.65% for sheep and lambs, and 3.95% for goats and kids. It can be said that the prevalence of hydatid cyst in liver and lung of sheep and lamb was significantly higher (Alian Samakkah et al., 2015).

In Yasouj industrial slaughterhouse, the highest prevalence of infection with *Fasciola hepatica* was reported in winter, including the highest in cows (12.5%) and the lowest in goats (7.16%) (Moshfe et al., 2016).

In Hamedan slaughterhouse, the highest level of *Fasciola* contamination was observed in cows (1.5%) and the lowest in sheep (0.5%). This study confirms the enzootic nature of *fasciola* in Hamedan. In this region, weather conditions including temperature, the amount of rainfall and the presence of water sources, are influential factors in the prevalence of *fasciola* (Piri et al., 2015).

In Gachsaran slaughterhouse, most of the cysts in the lungs and liver have been observed in sheep, and hydatidosis is more common in areas where sheep, goats and cows are reared traditionally. The highest rate of recorded liver and lungs is related to goats, including *Fasciola* (2.5%), liver hydatid cyst (2.05%), and pulmonary hydatid cyst (1.26%) (Ghasemiyan et al., 2012).

In Najafabad and Lanjan cities in Isfahan, the highest level of *dicrocoelium* contamination in sheep in Lanjan is related to spring (11.14%) and the lowest level is related to summer (5.86%). In Najafabad, the highest level of contamination is related to winter (4.47%) and the lowest in the summer (1.92%). The amount of goat *dicrocoelium* contamination in Lanjan is highest in the autumn (4.51%) and lowest in the summer (0.52%). In Najafabad, the highest contamination was related to spring (1.24%) and the lowest to winter (0.57%) (SabokteginRizi et al., 2016).

In Hamedan industrial slaughterhouse, the prevalence of infection with hydatid cyst was 12.3%, *Dicrocoelium* 6.5% and *Fasciola* 4.9%. The highest infection in cows was for hydatid cyst (16.2%) and *Fasciola* (9.5%), and in sheep, the highest contamination was with *Dicrocoelium dendriticum* (6.9%). In investigating lung and liver contamination, lung contamination with hydatid cyst (41.2%) and liver contamination (36.6%) and simultaneous contamination of liver and lung (22.2 %) was recorded. Also, the amount of parasite infection in old livestock is higher than in young livestock (Fallah et al., 2009).

In the survey of parasitic agents of sheep livers in the Miandoab slaughterhouse of West Azerbaijan, in the autumn season, out of a total of 1041 slaughtered sheep, 116 livers (14.11%) were recorded, and infection with hydatid cyst, *Fasciola*, *Dicrocoelium dendriticum*, and *Cysticercocystiniacoli* was found in 9 cases (76.7%), 7 cases (6.03%), and 94 cases (81.03%), 6 cases (17.5%), respectively. These figures suggested that the most common cause of seizure of livers in Miandoab city was *Dicrocoelium dendriticum* parasite (Jamshidi, 2015).

In Birjand slaughterhouse, out of a total of 1740 slaughtered livestock, of which 70 were camels and the rest were cows, sheep, and goats, 14 (20%) of the slaughtered camels were infected with hydatid cysts in their lungs, and in other livestock, 47 livers were infected with hydatid cysts (7.2%), 75 lungs were infected with hydatid cyst (31.4%), and the number of livers infected with *Fasciola* and *Dicrocoelium dendriticum* parasites were 54 (1.3%) and 29 (66.1%), respectively. Due to the high consumption of camel meat in that area, parasitism of this livestock becomes important (Malekpour et al., 2012).

In the investigation of the amount of parasitic infections (*fasciola*, *dicrocoelium dendriticum*, hydatid cyst and cysticercosis) in the liver and lungs of slaughtered cows in the slaughterhouse of Sarpol Zahab city (Kermanshah), out of 1170 slaughtered livestock, 417 (35.64%) were infected with parasitic diseases. Infection with hydatid cyst in the liver was seen in 95 cases (8.11%) and in lung in 236 cases (20.17%); cysticercosis infection in the liver in 8 cases (0.68%) and lung in 4 cases (0.34%); *Fasciola* and *Dicrocoelium dendriticum* infections in the liver were seen in 64 cases (5.47%) and 10 cases (0.85%), respectively. According to the results, this area is significantly infected in terms of parasitic diseases (Ghahoyie et al., 2014).

By comparing the above studies, it can be concluded that the level of pollution is different in different parts of the country. One of the main reasons for the variability of the level of pollution is the specific geographical and atmospheric conditions of the country, such as temperature, humidity, rainfall, etc. In fact, the suitable weather and climate causes the survival of many parasites in the environment. Moving livestock in different climates based on traditional and nomadic livestock husbandry (*Yilaq* and *Qashlaq*) and also buying and selling livestock in different provinces, have caused the spread and increasing progress of parasitic diseases in different areas. Of course, in rural areas, the use of livestock feces as livestock manure causes the pollution of fields and pastures, and in urban areas, the eggs of some parasites in the dried mud of sewage treatment plants can exceed the permissible limit and cause direct water pollution, as well as indirect use of sludge for various purposes such as agriculture. In fact, treatment plants in urban areas are also important in terms of the spread of parasitic diseases.

Isfahan province is one of the regions that hosts many parasitic diseases due to its centrality and balanced weather conditions and the high consumption of livestock proteins in the country. Moreover, human contamination has been reported in this province. In fact, common parasitic diseases can be an indicator of the health of people in that area. Among the parasitic diseases, there are cases such as fasciola, dicrocoelium, hydatidosis, which are the most important reasons for clinical referrals and occurrence of disease in some vital and nutritious organs such as the liver. They do not have obvious clinical symptoms. Cysticercosis in the meat of different livestock is nutritionally important due to their high food consumption. The main infecting parasites will be Fasciola, Dicrocoelium, Cysticercosis, Echinococcus-granulosus. In this research, the cases of contamination with such parasites and the changes that each parasite can cause in terms of pathogenicity, pathology, texture and nutrition have been examined macroscopically in order to observe and examine the changes that each parasite makes in the infected tissue.

MATERIALS AND METHODS

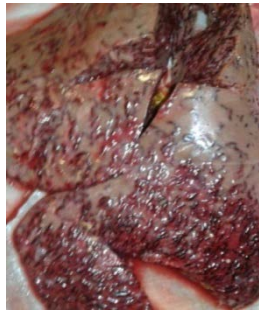Slaughterhouses are one of the important centers for tracking and investigating parasitic diseases, and due to the lack of clinical symptoms of most parasitic diseases, definitive diagnosis of these diseases is possible in autopsy and post-slaughter inspection. Therefore, a cross-sectional descriptive study by selective sampling method, considering the disease generation and tissue changes of infected organs such as liver, lung, heart and muscles was performed. The main aim of study was collecting statistical data related to each disease and also the detailed pathological interpretation of typical samples isolated in the fall season in Isfahan province. These data were analyzed in multiple phases:

First phase: visual inspection and sampling

Liver:

First, by examining the pollution macroscopically, the health of the organs was examined in terms of characteristics such as color change, volume, texture, etc. A healthy liver is chocolate brown in color and when it is placed on the examination table, it has sharp edges and completely sticks to the table, but the infected liver has rounded edges and does not place on the table. Moreover, hyperemia and superficial bleeding in melanosis, swelling of necrotic points, tumor, abscess, cyst, increase in the diameter of bile ducts, swelling of lymph nodes and white lines under the liver capsule, prominent points and tunnels full of blood and destroyed tissue remnants, are observed. Most of these problems are the result of the migration of parasites and in some cases the parasites themselves were visible on the surface of the organ, then by palpation the stiffness (cirrhosis of the liver), the surface adhesion was checked and by cutting the liver parenchyma diagonally in the navel of the liver (place of the biliary ducts and blood vessels) and the incision between Spiegel's angle and the liver and the pressure on both sides of the incision area is removed from the obstruction of the bile ducts or the discharge of bile pigment, and sometimes by observing the parasites Fasciola hepatica, gigantea and Dicrocoelium pi. Depending on whether the liver is infected or healthy, the presence of necrotic and cystic hydatid cyst grains is clear, some of which penetrated into the parenchyma and contained clear and transparent liquid, while others contained dark colored liquid and in the section of the cysts, small and large holes were observed with a gelatinous layer with a white wall. In cases of Dicrocoelium contamination, it was removed even with the observation of a single number of liver parasites, but in Fasciola, only

acute cases with high contamination that could not be corrected were removed and the rest were corrected. In the case of hydatid cyst, local recording of the infected organ was also performed.



B- Infected liver

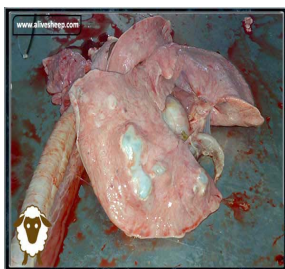


A. Healthy liver

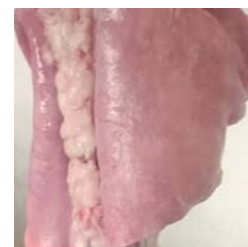Figure 1. Sample of a sampled liver

Lung

The natural color of the lung is pink-gray, after being placed on the examination table, the blood and surface secretions of the lung were cleaned for a more detailed observation. The color change and bleeding, the size of the lymph nodes, and the volume of the lung were checked. Then the lung was touched well and examined for the presence of tumors, abscesses, etc. (balloon condition), collapse (disappearance of air sac spaces and lung contraction), hepatogenesis (filling of lung bronchi with tissue and secretions) and parasitic lesions. Then the researcher proceeded to cut the right and left lymph nodes on both sides of the trachea, and then the mediastinal lymph nodes between the aorta and esophagus, and then made a transverse cut on the diaphragmatic lips. By pressing on both sides of the cut, the presence of blood and food secretions, parasites, and parasitic lesions were investigated. Parasites such as fasciola and hydatid cyst were observed. In cases of contamination, due to the low economic value of the lungs, the infected lungs were removed and sampling was not done.



B. Infected lungs



A- Healthy lungs

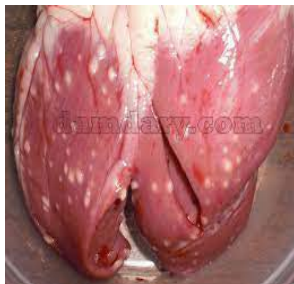Figure 2. Sample of a sampled lung

Heart

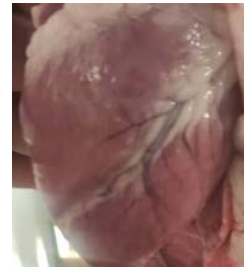First, the outer membrane of the heart is examined for pericarditis and hydropericarditis, and the pericardium is cut and the heart is removed. Geart is examined for color change, volume, and the presence of necrotic grains and parasitic cysts, and then by touching the heart, the firmness and laxity and the consistency of the fats around it are examined. Then it was cut and made 3 longitudinal cuts

between the left ventricle and the left atrium. Between the right ventricle and the right atrium, we make a deep incision between the muscles of the 2 ventricles, and the existence of cysticercosis in the cut areas and valves is checked.

In fact, the purpose of the heart inspection is the presence of parasites such as cysticercosis and hydatid cyst, and the purpose of cutting is only to check the presence of cysticercosis. If it is observed in the heart and not in the other areas, local removal is performed (in a complete examination of muscles such as the masseter and tongue, inspection of the head and triceps muscle and vertebral column was performed). If the parasite is present, first in the master muscle and then in the heart and the vertebral column by cutting the parasite, samples were taken from the infected areas to check the changes caused by the parasite.



B- Infected heart

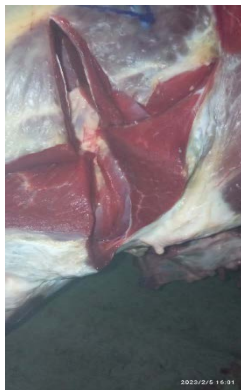

A- Healthy heart

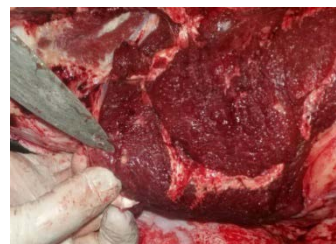Figure 3. Sample of a sampled heart

Muscles

In order to check the contamination of muscles with cysticercosis, cuts must be made in certain areas of the carcass (head muscles, tongue, diaphragm, heart, triceps muscles and spine). Some cases in the form of pea-like nodules, like fat cells (they could not be moved with the tip of a knife), were observed deep in the muscles. If more than 2 cysts were observed in a scattered manner or 2 cysts were observed in one incision site, total removal was performed, otherwise thermal healing was performed. The study of cases of contamination was observed only in muscles.



B- Healthy Beef triceps



A- Infected Beef triceps

Figure 4. Sample of a sampled muscle

Phase II: Sampling

For more accurate sampling and to prepare the necessary conditions, the selected samples from the slaughterhouse were transported to the pathology laboratory by maintaining the temperature of 0-4, and recording the exact characteristics of the sampling on the containers. The separation of the tissue samples was done in the laboratory. Taking into consideration the tissue changes and destruction by parasites, photographs were taken of typical cases of contamination in the infected organ and carcasses to familiarize with the appearance of complications caused by parasites. Then, 5 cm of the infected area was separated with a scalpel and placed in a 10% formalin container (in a diluted form, 90 cc of water is added for 10 cc of formalin). Then, $\frac{2}{3}$ of formalin was poured into the container (glass containers with lids were chosen) and placed on the container having the necessary information.

The third phase: Microscopic examination

In this phase, by preparing microscopic sections by the laboratory pathologist, the changes caused by the parasites were checked, which includes 3 parts that were done in the laboratory (Due to the availability of healthy histopathological samples, tissue sections were not prepared from healthy samples).

- 1-Preparation of microscopic section
- 2-Slide preparation and staining
- 3-Observation and microscopic examination

Tissue processor model 9602DS was used to prepare tissue section and passage for clarifying and preparing the sample for histopathological studies. In general, tissue preparation was done faster with this device. The sample container containing 10% formalin was poured into the first container of the TissueProcessor device (the device contains 12 containers). The first and second containers of the machine contain formalin, and the sample was placed in them for one hour. Then the sample was put into the third container containing 70 degree methyl alcohol. 70 degree alcohol was prepared from 96 degree alcohol and diluted with distilled water, so that for 100 cc of 96 degree alcohol, 37 cc of distilled water was added to obtain 70 degree alcohol and in container no. 3 devices were poured. Then, it was kept in container number 3 for 1 hour and then entered into container number 4 which contained 80% methyl alcohol (100 cc of 96 degree alcohol and 20 cc of distilled water). For 1 hour, the sample was in container number 4; then it was placed in container number 5, which contained 90 degree methyl alcohol (100 cc of 96 degree alcohol and 6 cc of distilled water) and was in container 5 for one hour. Then it entered container number 6 which contained 96 degree methyl alcohol and was in container 6 for 1 hour and 15 minutes and then entered container number 7 of the machine which contained 96 degree alcohol. It was in this container for 1 hour and 30 minutes, and then it entered the next container containing absolute alcohol, and it remained in that container for 2 hours, and then into container 9 containing xylyl for clarification and alcohol.

It was kept in container number 9 for 2 hours, and container 10 also contained pure xylene in the same way, and the sample remained in this container for 2 hours. In fact, a total of 4 hours of the sample remained in the gel. Then it was transferred to containers 11 and 12 which contain liquid paraffin. Each of them was paraffinized for 2 hours for a total of 4 hours (the paraffin used had favorable characteristics in terms of melting temperature of 56-59 degrees without impurities and also the

lowest amount of fat (it should not have more than 2% fat). Each solution bottle was 250 cc (with a diamond pen, the numbers of the samples were recorded on the slides). We place the mold in the middle of the mold so that the cutting surface of the tissue is under the mold. The mold is made of L-shaped aluminum, which is placed on a greased glass slab (the molds were greased with Vaseline) and a little paraffin is melted by the DS4LM paraffin dispenser. Poured on the bottom of the mold and after planting the heated sample in the middle of the paraffin, fill the rest of the mold with paraffin in the correct way and after 15 minutes after the mold has hardened, put the sample in the oven to harden faster. By opening the mold, the paraffin block containing the samples is ready to be cut, and it is fixed on the block holder towards the blade of the D69502 rotary microtome device, and the blade and block are first layered with the adjusting screw. The zinc paraffin is cut until it is close to the sample, then we touch the surface of the block with the side of the microtome blade. Then we set the degree of the microtome to 5 microns and started to cut the tissue and prepare a tissue slide up to the end of the sample, and then put the prepared slides with flat tweezers so as not to damage the sections inside the container with 96% methyl alcohol solution (one volume of alcohol and two volumes of water) and return the wrinkles of the prepared section. Then it was transferred to a DS9008 bain-marie (tissue bath) and the samples were floated on the surface of the water and covered with albumin glue by a clean slide from the surface of the water.) were caught and then the slides containing the sections were placed inside the furnace until the excess paraffin melted and the samples stuck to the surface of the slide.

After half an hour, put the slides into a container containing purified xylene (for paraffin and clarification) and put them in xylene container number 1 for 10 minutes and then another 10 minutes in xylene container number 2 for a total of 20 minutes and then place 70-90-80% methyl alcohol in the containers in descending order for one minute, and then wash well with running water until the clear water comes out and the slides become completely transparent, and then put the slides into the container containing the dye. It was stained with hematoxylin and kept in the dye for 10 minutes and (if the sample doesn't get dyed, it will remain in the dye a little longer), washed well again in running water, and then put in a container containing alcohol acid (alcohol acid from mixing 1000 cm A cube of 70 degree methyl alcohol was prepared with 10 cubic centimeters of hydrochloric acid.)

After washing in the running water, the slides were put in the lithium carbonate solution and quickly take them out and wash them again in running water to clean the excess parts around the sample on the slide. Then put it in a container containing eosin dye for 15 seconds and wash it in running water until it is completely clean. Then, in order to remove the water, or so-called dehydrating, again use containers containing 100-70-80-90% alcohol in ascending order (enter and exit the container quickly). After dehydrating for de-alcoholizing and clarifying the cross section, 2 xylene containers were used again for 5 minutes for a total of 10 minutes. Then, in order to mount, a coverslip suitable for the size of the sample was used and 2 pieces of glue (the amount of glue should be enough so that air bubbles do not get under the coverslip), the coverslip was placed on the sample and the coverslip was glued, and the coverslips were arranged in this order. Microscopic examination was prepared.

Pathological slides prepared to observe and report histological changes first with 40 magnification to detect clear and transparent samples and then with 100 magnification to photograph the fields of view that are important for diagnosis in terms of pathological tissue reactions.

FINDINGS

The findings of this research were presented in the form of statistical data in terms of the number and percentage of prevalence, the amount and type of contamination in different organs of livestock slaughtered in the autumn season of Isfahan Industrial Slaughterhouse, along with macroscopic examination of infected tissues and laboratory examination of histopathological changes in the tissues of important organs in terms of zoonotic and nutritional value, such as liver and muscles.

According to table 1, it is clear that the total number of slaughters in the industrial slaughterhouse of Isfahan in the months of October, November and December was 60,881 livestock, of which 19,958 livestock had parasites. The number and types of parasites by livestock are as follows.

32213 sheep were slaughtered, of which 167 sheep (0.84%) had fasciola and 5780 sheep (28.96%) had dicrocoelium. In total, 11993 sheep (60.09%) were infected with some kind of parasite.

Also, 21368 goats were slaughtered, of which 13 goats (0.07%) were infected with cysticercosis parasite, 1354 goats (6.78%) were infected with hydatid cysts, 98 goats (0.49%) were infected with Fasciola, and 3918 goats (19.63%) were infected with dicrocoelium. A total of 5383 goats (26.97%) were infected with some kind of parasite.

2582 cows and calves were slaughtered, of which 9 cows (0.05%) were infected with cysticercosis, 2521 cows (12.63%) were infected with hydatid cysts, and 52 cows (0.26%) were infected with fasciola. In total, 2582 cows (12.94%) were infected with some kind of parasite. Moreover, 55 camels and 1059 ostriches were killed, and no parasitic diseases were observed in them.

Table 1- Table of frequency distribution and frequency percentage of parasitic infections of slaughtered animals in Isfahan industrial slaughterhouse in October, November and December 2022

TYPE OF LIVES-TOCK		CYSTIC CIRCUS	HYDATID CYST	FA-CIOLA	DICROS-LIUM	TOTAL NUMBER OF PARASITES	TOTAL NUMBER OF KILLING
Sheep	Number	54	5992	167	5780	11993	32213
	Percent	0.27	30.02	0.84	28.96	60.09	
Goat	Number	13	1354	98	3918	5383	21368
	Percent	0.07	6.78	0.49	19.63	26.97	
Cow & calf	Number	9	2521	52	-	2582	6186
	Percent	0.05	12.63	0.26	-	12.94	
Camel	Number	-	-	-	-	-	55
	Percent	-	-	-	-	-	
Ostrich	Number	-	-	-	-	-	1059
	Percent	-	-	-	-	-	
Total	Number	76	9867	317	9698	19958	60881
	Percent	0.38	49.44	1.59	48.59	100	

It should be noted that the percentages in the table are based on the number of infected livestock, ie compared to 19958.

According to table 2, it is clear that in the industrial slaughterhouse of Isfahan in the months of

October, November and December 2022, 60,881 livestock were killed, of which 19,958 livestock had parasites, and 64.21% liver, 35.40, and 38.00 lungs. 0% of the carcasses were seized and 60.09% of the sheep had parasites, of which 39.80% of the liver, 20.02% of the lungs and 0.27% of the carcasses were seized.

The cysticercosis parasite was found in the carcass of 54 sheep (0.27%), the cysthydatid parasite was found in the liver of sheep in 1996 sheep (10.00%), and 3996 (20.02%) in the lungs of sheep and a total of 5992 infected organs (30.02%) was recorded from sheep slaughtered due to cysthydatide contamination. Fasciola parasite was found in the liver of 167 sheep (0.84%), Dicrocoelium parasite was found in the liver of 5780 sheep (28.96%). 26.97% of the goats had parasites, of which 21.17% liver, 5.74% lung and 0.06% carcass were recorded.

Cysticercosis parasite was found in 13 goats (0.06%), hydatid cyst parasite in 209 goats' liver (1.04%) and 1145 (5.74%) in goats' lungs. A total of 1354 infected organs (6.78%) was recorded from slaughtered sheep due to infection with hydatid cyst. Fasciola parasite was found in the liver of goats in 98 sheep (0.49%), Dicrocoelium parasite was found in the liver of 3918 goats (19.63%), 12.94% of the cows had parasites.

Cysticercosis parasite was observed in 9 cows (0.04%), hydatid cyst parasite was found in 596 cows (2.99%) in the liver of cows and 1925 (9.65%) in the lungs of cows. A total of 2521 infected organs (12.63%) of slaughtered cows were recorded due to infection with hydatid cyst. Fasciola parasite was observed in the liver of 52 cows (0.26%).

Table 2: Table of frequency distribution and frequency percentage of pulmonary, hepatic and meat parasites in slaughtered animals in Isfahan industrial slaughterhouse in October, November and December 2022

NUMBER OF KILLING		CERCOSIS CYST	HYDATID CYST	FAS-CIOLA	DICROS-LIUM	TOTAL INCI-DENCE	TOTAL		
Sheep	Corpse	Number	54	-	-	54	32213		
		Percent	0.27	-	-	0.27			
	Liver	Number	-	1996	167	5780		7943	
		Percent	-	10	0.84	28.96		39.80	
	Lung	Number	-	3996	-	-		3996	
		Percent	-	20.02	-	-		20.02	
	Total	Number	54	5992	167	5780		1193	
		Percent	0.27	30.02	0.84	28.96		60.09	
	Goat	Corpse	Number	13	-	-		13	21368
			Percent	0.06	-	-		-	
Liver		Number	-	209	98	3918	4225		
		Percent	-	1.04	0.49	19.63	21.17		
Lung		Number	-	1145	-	-	1145		
		Percent	-	5.74	-	-	5.74		
Total		Number	13	1354	98	3918	5383		
		Percent	0.06	6.78	0.49	19.63	26.97		

Cow & calf	Corpse	Number	9	-	-	9	6186			
		Percent	0.04	-	-	0.04				
	Liver	Number	-	596	52	-		648		
		Percent	-	2.99	0.26	-		3.25		
	Lung	Number	-	1925	-	-		1925		
		Percent	-	9.65	-	-		9.65		
	Total	Number	9	2521	52	-		2582		
		Percent	0.04	12.63	0.26	-		12.94		
	Total	Corpse	Number	76	-	-		-	60881	
			Percent	0.38	-	-		-		-
		Liver	Number	-	2801	317		9698		1281
			Percent	-	14.03	1.59		48.59		64.21
Lung		Number	-	7066	-	-	7066			
		Percent	-	35.40	-	-	35.40			
Total		Number	76	9867	317	9698	19958			
		Percent	0.38	49.44	1.59	48.59	100			

In sheep, the most cause of seizure of carcasses was related to cysticercosis parasite, the most cause of seizure of liver was related to *Dicrocoelium* parasite, the least was related to *Fasciola* parasite, and the most cause of seizure of lungs was due to hydatid cyst parasite, which can be concluded that hydatid cyst parasite causes the most lesions in this livestock.

In goats, the most cause of seizure of carcasses was related to cysticercosis parasite, the most cause of liver seizure was related to *Dicrocoelium* parasite, the least was related to *Fasciola* parasite, and the most cause of seizure of lungs was due to hydatid cyst parasite, which can be concluded that *Dicrocoelium* parasite causes the most lesions in this livestock.

In cows and calves, the most and only reason for the seizure of carcasses is related to cysticercosis parasite, the most liver seizure is related to hydatid cyst parasite, and the least is related to *fasciola* parasite, the most and only reason for seizure of lungs is due to hydatid cyst parasite, which can be concluded that the most lesions in this parasite are Creates a hydatid cyst.

In the fall season, the amount of parasitic infection is assigned to hydatid cyst, then *dicrocoelium*, then *fasciola*, and finally cysticercosis. As a result, the highest contamination in autumn season is related to hydatid cyst parasite and the lowest is related to cysticercosis parasite.

According to Figure 5, out of a total of 60,881 slaughtered and examined livestock in the fall season of 19958, it was observed that 49.44% were infected with hydatid cyst, 48.59% with *dicrocoelium*, 1.59% with *Fasciola* parasite and 0.38% were infected with cysticercosis. It can be said that the highest parasitic infection in this season is related to hydatid *dicrocoelium* cyst and the lowest is related to *Fasciola* and cysticercosis.

Statistics of October 2022, Isfahan industrial slaughterhouse							
Recorded livers				Recorded carcasses of livestock		Species of livestock	Row
Dicroslium	Fasciola	Hydatid cyst	Cystic circo	Cystic circo			
1783	47	714		12	11628	Sheep	1
1114	34	64		4	7704	Goat	2
	23	237		4	1864	Cattle and	3
					25	Camel	4
					295	Ostrich	5
2897	104	1015		20	21516		Total

Statistics of November 2022, Isfahan Fasaran industrial slaughterhouse							
Recorded livers				Recorded carcasses of livestock		Species of livestock	Row
Dicroslium	Fasciola	Hydatid cyst	Cystic circo	Cystic circo			
1983	56	639		16	10775	Sheep	1
1318	27	76		6	7246	Goat	2

Figure 5 - Distribution chart of the percentage of incidence of various parasitic infections in all animals studied in Isfahan Industrial Slaughterhouse in October, November and December 2022

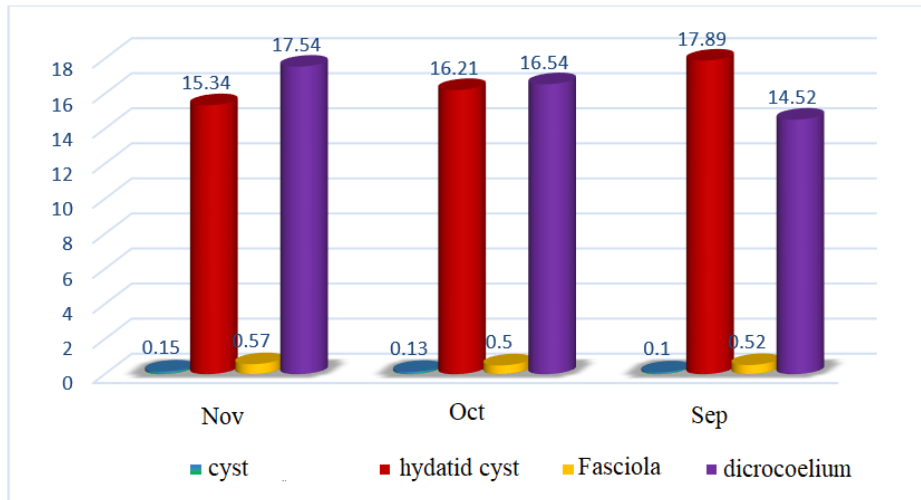


Figure 6 - Distribution chart of the percentage of incidence of various parasitic infections in all animals studied in Isfahan Industrial Slaughterhouse by October, November and December 2022

As can be seen in Figure 6, in October, 17.89% hydatid cyst, 14.52% dicrocoelium, 0.52% Fasciola, and 0.1 % cyst were observed, and in November the process of hydatid cysts declined to 16.21% but increased to 16.54%. The amount of Fasciola was reduced (0.5 %). In December, the amount of hydatid cysts decreased as the previous month and rose to 15.34 %, and the amount of dicrocoelium increased to 17.54%, and the amount of Fasciola increased similar to the previous month. It was up to 0.57%, but the cysticercosis rate increased the same as the previous month and was 0.15 %. The highest contamination of hydatid cysts was in October and the lowest in December. The highest contamination of dicrocoelium was in December and the lowest contamination in October. The highest contamination of fasciola was in December and the lowest in November. Also, the highest contamination of cysticercosis was in December and the lowest in October. It can be said that, with

the start of December, the prevalence of hydatid cyst was lowered, but for dicrocoelium, fasciola and cysticercosis was increased.

DISCUSSION AND CONCLUSION

By examining the appearance of the liver, the appearance of the liver can be distinguished from each other that the liver appearance is in the form of bleeding and fibrosis, but in the liver dicrocoelium, the liver dicrocoelium is almost healthier and has an almost healthy appearance and in the liver dicrocoelium. In the liver contaminated with hydatid cysts, pear-shaped cysts containing watery liquid were seen (Figure 7).

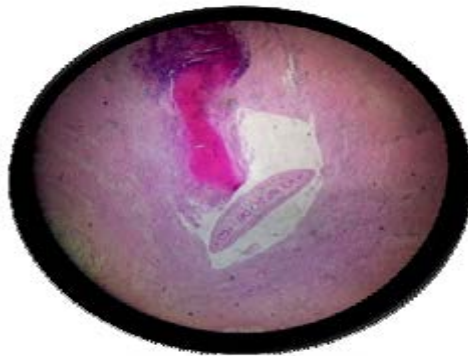


Figure 7. Pathological view of the sheep

By examining the pathological changes of the liver by magnifying 40 fasciola, it can be said that by thickening the bile ducts, the smaller bile ducts and the irregular fibrosis and coagulation necrosis are caused by the poisonous secretions of the parasitic bile hypertrophy. In the dicrocoelium of bile ducts, the bile and thick green liquid, and the hyperplasia, the fibrosis of the liver, causes the liver cirrhosis of the liver than the fiber. But the immigration lesion and toxic secretions do not cause the liver parenchyma, and the amount of tissue destruction of the dicroceceliasis is lower than that of the fasciola, and with a significant increase in gabbels, plasmasles and macrophages as well as some eosinophyll cells. The presence of traumatic cells and the secretions of single -core cells around bile ducts such as lymphocytes and tissue cells and the creation of severe hyperplasia collagen of epithelial cells are seen in Figure 8, but no immigration lesion is in the liver paraniles and only the widespread reproduction of the glands and the complete duct of the liver tissue is evident and the liver cirrhosis is seen, which ultimately becomes rigid and fiber tissue.

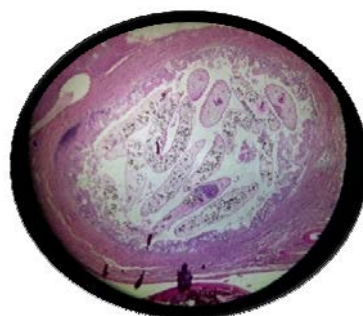


Figure 8- Pathological view of dicrocoelium in sheep liver

In hydatid cyst, swelling and hyperplasia and thickening of the bile ducts and swelling of the liver lobes due to hyperplasia and inflammation of the mucous membranes from the secretion of mononuclear cells, lymphocytes, macrophages, eosinophils and plasma cells are clearly evident. In the investigation carried out with 100 magnification in the bile ducts and false tunnels created by the parasite, destroyed hepatocytes and eosinophils along with the infiltration of eosinophils in the stage of hepatocyte cyst destruction as A line with pyknotic nuclei and large spaces of DISS with the formation of granule tissue in the cystic space along with granuloma of multinucleated cells, histiocytes and lymphocytes and wide bands of collagen and fibrosis were observed.

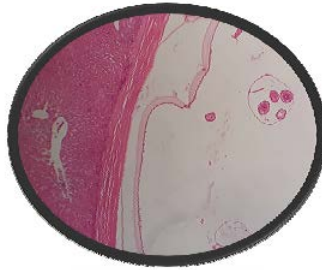

Figure 9. Pathological view of hydatid cyst in sheep liver

Infection with hydatid cyst in fig. 9 is more severe than *Dicrocoelium*, and infection with *Fasciola* is the least severe. In severe infection, hydatid cyst and liver fasciola are removed, but in mild infection, local removal is done. *Dicrocoelium* is removed even by observing a liver parasite.

The size of the cysticercosis cyst in fig 10 is smaller than the hydatid and has a thicker wall containing clear to cloudy viscous liquid and its origin is muscles. Giant histocyte cells along with fibro-calcification and finally fibrosis of the supporting stroma of the parasite and calcification of the parasite remains, which in cases of low contamination (less than 2 cysts in one cut or 10 cysts in different areas of the carcass) local removal and sanitization Heat treatment is done, otherwise the total removal of the carcass is done.

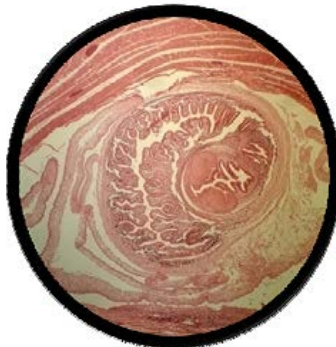


Figure 10. Pathological view of cysticercosis in cow muscles

According to the research conducted by other researchers in this field, it can be concluded that factors such as livestock age, gender and geographical region do not have a significant effect on the increase of contamination, but the high level of parasitic contamination and many diseases in productive livestock (female sex) cannot be ignored. Because the possibility of the continuation of the parasite cycle in the

livestock's body is increasing and every year the level of contamination is increasing compared to the previous year, but the amount is not significant. For this reason, it was not investigated in this study. Also, due to the movement of herds for feeding (nomads-Yilmaq and Qeshlaq) and the movement of live livestock in the slaughterhouses for slaughter, the cases of contamination cannot be attributed to the livestock population of that region, which required the necessary planning to eradicate it, as a result of the climate cannot be considered as a suitable factor for the level of contamination, but considering the four seasons of the weather in our country, Iran, and the importance of weather conditions in the proliferation and spread of parasites, it can be concluded that the weather conditions of each region will play a significant role in the severity of parasitic infections, and considering Autumn season was considered in this study due to the special weather conditions (heat at the beginning of the season and cold at the end of the season) to investigate the pollution cases of this season and it was significant as a variable. According to the daily survey in the slaughterhouse and using statistical software, the results were that the prevalence of hydatid cyst decreased with the cooling of the air and the level of contamination with *Dicrocoelium* and *Fasciola cysticercosis* parasites increased. In the fall season, the level of parasitic infection was as follows, first hydatid cyst, then *dicrocoelium*, then *fasciola*, and finally *cysticercosis*, the highest infection was related to hydatid cyst and the least infection was related to *cysticercosis*.

According to the investigation of contamination in other parts of the country and compared with the study done, the contamination with hydatid cyst in the liver and lungs of goats and cows was more than in other parts of the country, but the contamination in the liver and lungs of sheep and camels was less.

Fasciola infection in the liver of sheep and cows was the highest compared to other parts of the country, but the lung infection with *Fasciola* was less than other parts of the country.

Dicrocoelium contamination in sheep-goat liver has been higher than in other parts of the country. *Cysticercosis* contamination in sheep carcasses has been higher than in other parts of the country.

Regarding the difference between the level of contamination of livestock slaughtered in Isfahan in 2022 and other studies conducted by researchers in other parts of the country during other years, the following points can be mentioned:

1- The geographical area due to the different climatic conditions (desert areas in the east of the province and mountainous areas in the west of the province, etc.) in different parts of the province and the vastness of this province can be a suitable factor for the high incidence of parasitic diseases in this province.

2- Due to the large population of this province and the significant consumption of livestock proteins, as well as the increasing growth of the industry and the decrease in agriculture and livestock husbandry (increasing urbanization), a significant amount of livestock has been imported to this province from different parts of the country, and it can be said that a significant percentage of the slaughtered livestock belongs to this province. As a result, the amount of parasitic contamination with the entry of low-yielding, infected, weak and sick livestock (due to the increasing price of feed and fodder, livestock productivity is taken into consideration by livestock farmers and low-yielding livestock is removed) from other parts of the country to the livestock field of Isfahan province leads to an increase

in parasitic contamination in this province.

3- Due to unfavorable economic conditions and price increase and lack of anti-parasitic drugs, livestock farmers cannot afford to buy anti-parasitic drugs.

4- Due to the drought and lack of fodder, the number of traditional livestock farmers has decreased and industrial livestock farmers are forced to procure fodder from outside the province. This can also play a significant role in increasing pollution in this province.

5- Due to the reduction of pasture and water for cultivation and the allocation of cultivated areas to human food (legumes and vegetables, etc.), livestock farmers have faced a shortage of fodder and an increase in prices, and they have been under pressure from an economic point of view, which has led to the discouragement of livestock farmers towards This occupation and as a result of removing a significant amount of productive livestock, which can also increase parasitic contamination, because the amount of parasitic contamination in old livestock is higher than that of young breeding livestock, and by comparing the amount of contamination compared to previous years, the percentage Pollution has increased.

6- Due to the lack of 100% sufficient control over all the cases in the slaughterhouse by the veterinary inspectors, including the removed and contaminated cases, and due to the increase in the keeping of pets, including dogs, and the concern about their food, a significant percentage of the cases removed by the inspectors, slaughterhouses and butchers were removed from the slaughterhouse and sold. As a result, it will complete the cycle and increase parasitic diseases.

7- Traditional thoughts in some regions of the province regarding the consumption of liver in raw form (tonic and treatment of anemia) have caused an increase in human infections, so that in the case of some parasites, Isfahan province has a special place in the country.

As a result, in a general overview of the study, it can be said that except for the infection with hydatid cysts in the liver and lungs of sheep and camels, this province has a record in terms of other parasitic diseases and the percentage of infection, and it has a special place. As a result, this study is important from several points of view. is In terms of health, food and the importance of the changes that occur in the tissue of organs such as the liver with the consumption of useful foods by parasites, which, due to the eating habits of people and the high consumption of livestock proteins, reduce the nutritional value and waste protein resources. As a result of the local removal of infected cases and in terms of completion of the life cycle of the parasite, which causes the spread and stability of the parasitic disease in the society, and this is important in distinguishing these diseases from the point of view of slaughterhouse inspection in veterinary medicine and Thus, according to the few studies regarding the investigation of histopathological cases of sensitive organs such as the liver in human samples in order to diagnose and differentiate the data by generalizing the histopathological complications and the similarity of the course of the disease in humans and livestock, an accurate interpretation of the course of the diseases It will be helpful in evaluating the pathogenesis of the disease in humans and will play an important role in raising the awareness of those involved in diagnosis and treatment so that they can prevent the health and economic damage caused by basic planning.

Conflict and interest: The authors have no conflict of interest.

Contribution by author: The authors are responsible for all components of this work.

Funding or funds: No financial support was provided.

REFERENCES

- Jamshidi, K., Aghabigi, B. and banhashem R. (2015). Slaughterhouse study of parasitic agents of sheep liver confiscation, Miandoab, West Azerbaijan. National Conference on Common Diseases between Humans and Livestock. 1, 89-99.
- Hamzavi, Y., Avdparandin. F. Faizi, F., Sardari M. (2018). The rate of hydatid cyst infection in slaughtered animals in Asadabad slaughterhouse during 2014-2015. *Journal of Researchers*. 12 (3): 58-66.
- Saboktegin, H., PirAli Khairabadi, Y., Muqtada Khorasgani, A. (2018). Evaluation of *Dicroslium dendriticum* infection in sheep and goats in Najafabad and Lenjan abattoirs in Isfahan province and pathological lesions in the liver. *Animal Biology* 1397. 11 (1): 27-33.
- AlianSamakkhah, Sh., RahmaniSokhtAbandani, M., Khanzadi, S. (2015). Prevalence of parasitic infections in the liver and lungs of slaughtered animals in industrial slaughterhouses in Mazandaran province in 2015. *International Conference on New Technologies in Science*. 13 (4), 901-922.
- Falah. M., Matini, M., Kia Ashrat, Andmbedi. A. 2011 Prevalence of human and animal parasites (hydatid cyst, liver trematodes and sarcocystis) in slaughtered animals in Hamadan Industrial Abattoir in 2009. *Scientific Journal of Hamadan University of Medical Sciences and Health Services*. 7 (3): 5 - 12.
- Qasemian Creek A., Abbasi Hormozi, A. (2008). Investigation of the causes of recording the liver and lungs of sheep and goats slaughtered in Gachsaran abattoir. *Veterinary clinical research*. 4 (3): 199-211.
- Ghahoyi. A., Naqibi, N., Zeynalzadeh A., 2020. Evaluation of parasitic infections (*Fasciola*, *Dicroslium*, hydatid cyst and *Cercus* cyst) in the liver and lungs of cows slaughtered in Sarpol-e-Zahab slaughterhouse (Kermanshah) during 1993 and 1994. *Journal of Knowledge and Health in Basic Medical Sciences of Shahroud*. 214 (2): 15 - 22.
- Moshfe, A., Bagheri, M. MohebbiNobandagani, Z. (2005). Prevalence of *Fasciola hepatica* parasite in slaughtered animals in Yasouj industrial slaughterhouse 2002-2003. *ArmaghaneDanesh Magazine*. 2 (3): 25-32.
- Malik P., Mohammadyari, N. (2012). Investigation of infection with *fasciola*, *dicroslium*, hydatid cyst and sarcosis killed in Birjand slaughterhouse in summer 2012. *Veterinary laboratory research* 139. 4 (1): 232.
- Arbabi Mohsen, Nader Pistachio Chians, TavassolKhamsehHadi, Hoshyar Hossein, Delavari Mehdi, 2016, Molecular Identification and Geotaping of *Echinococcus* \rightarrow *Granulorus* Strains Isolated from Camels and Dogs in Isfahan Region, Department of Parasitology, Kashan University of Medical Sciences, 21(2), 122 to 126.
- Bina Bijan, Movahedian Attar Hossein, Amini Ahmad Ali, 2004, Investigation of the quality of dried sludge of Isfahan wastewater treatment plants and its application for different uses of water and wastewater, 15(1), 34-42.
- PiriKobra, Maghsoud Amir Hossein, Matini Mohammad, Fallah Mohammad, 2015, Prevalence and severity of *Fasciola* infection in slaughtered animals in Hamedan slaughterhouse, *Ibn Sina Clinical Medicine*, 24(2), 164-170.
- HamzaviYazdan, Nazari Nasser, Mikaeli Ali, ParandinFatemeh, FeiziFariba, Sardari Mohammad, 2015, The rate of hydatid cyst infection in slaughtered animals in Asadabad slaughterhouse, *PajouhanBahar* 2016, 14(3), 58-66.
- Heidarian Mohammad Taghi, BoashaghiHamzeh, 2012, Study of camel liver worm infection in Semnan city, *Veterinary laboratory research*, 4(1), 113-118.
- Qasemian Creek Amolbinin, AbbasiHormozi Ali. (2013) Investigating the causes of recording liver and lung of sheep and goats slaughtered in Gachsaran abattoir, *Veterinary Clinical Research*, 4(3) 199-211.